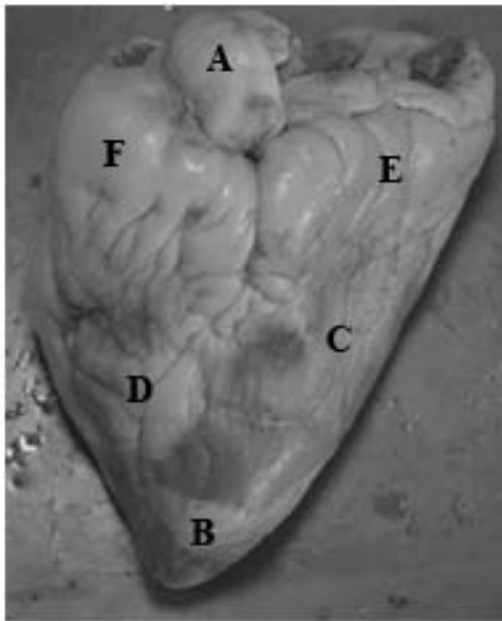


SHEEP HEART



- A. Aorta
- B. Apex
- C. Left Ventricle
- D. Right Ventricle
- E. Left Atrium (beneath fat)
- F. Right Atrium (beneath fat)

Examine the external surface of the heart, and notice the accumulation of fats, or adipose tissue. Identify the apex of the heart. In this position, notice the arched aorta extending from the superior portion of the heart.

Figure 4.1

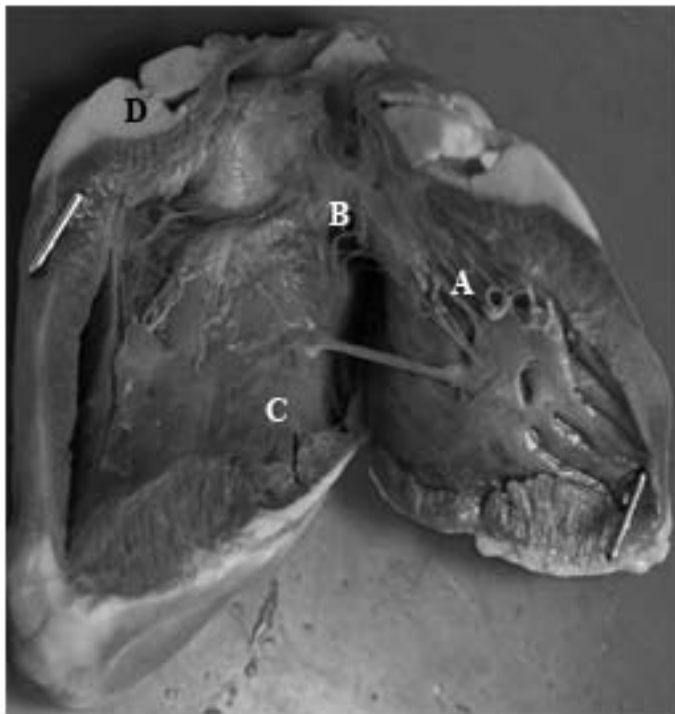


Figure 4.2

- A. Chordae Tendinae
- B. Left Atrium
- C. Left Ventricle
- D. Adipose Tissue

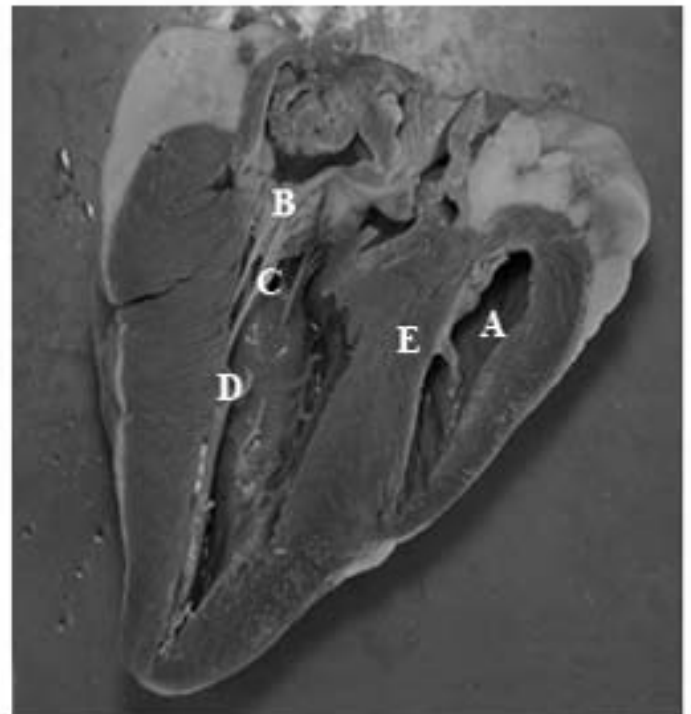


Figure 4.3

- A. Right Ventricle
- B. Bicuspid Valve
- C. Chordae Tendinae
- D. Papillary Muscles
- E. Interventricular Septum